

Info shared by Pitbull SA.
Manjaro APBT kennel.
South Africa.

My Website www.pitbullsa.co.za

My E mail "manjaro@pitbullsa.co.za"

My Facebook "Gawie Manjaro"

My Facebook page "Manjaro Kennel"

My mobile +27827838280.

Zello.com "VoIP" – ask for info.

About dental anatomy.

Teeth are very important to an animal as they are used for eating, grooming and defence.

Consequently, dental problems, if not treated, often lead to more generalized illness and affect the immune system.

Mammals have teeth of different sizes and shapes, a condition known as heterodonty, allowing different teeth to be specialized for different tasks.

These specialized teeth include:

Incisors (I)

Canine teeth (C)

Premolars (P)

Molars (M)

Mammals also have two sets of teeth: a deciduous set (milk teeth, baby teeth) and a permanent set.

Dental formulae.

Dental formulae are used to indicate the number of each type of tooth for a given species.

Because the jaw is bilaterally symmetrical, only one half of the jaw is described.

The incisors are indicated first, followed by the canine, premolars and molars.

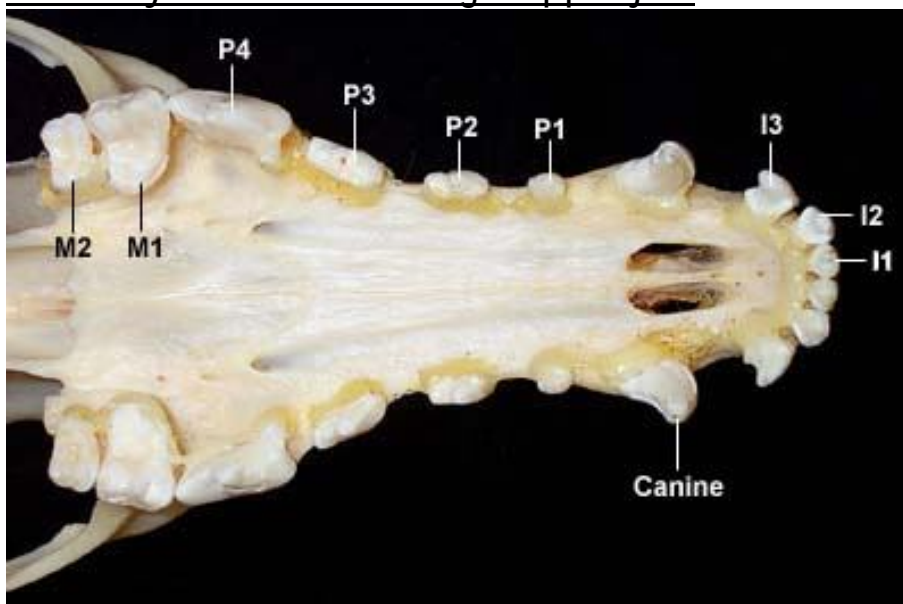
The maxillary arcade or upper jaw is listed over the mandibular arcade or lower jaw.

For instance, a dog has 3 incisors, 1 canine, 4 premolars and 2 molars on one side of the upper jaw and 3 incisors, 1 canine, 4 premolars and 3 molars on one side of the lower jaw, so the dental formula would be:

<u>upper</u>	<u>I C P M</u>	<u>3 1 4 2</u>
lower	I C P M	3 1 4 3

Individual teeth can also be denoted: The first lower incisor would be I₁ and the second upper molar would be M².

Maxillary arcade of the dog – upper jaw



Anatomy of teeth.

There is considerable variation in dental anatomy among animals. In mammals, there are two distinctive types of teeth that differ in pattern of growth and morphology:

Brachydont or low-crowned teeth.

These are what is seen in man, carnivores such as dogs and cats, and pigs.

This type of tooth consists of a crown above the gingiva
a constricted neck at the gum line
a root embedded in the jawbone.

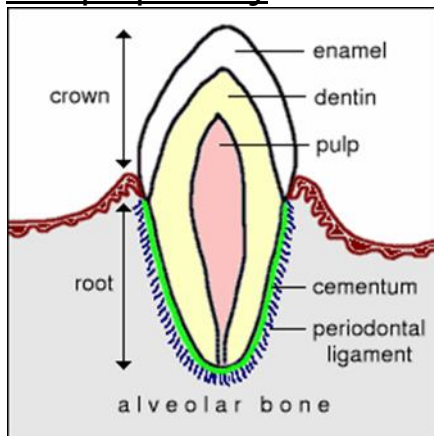
The crown is encased in enamel and the root in cementum.

Enamel is the hardest substance in the body being densely packed with hydroxyapatite (mineral) crystal and heavily mineralized with calcium salts.

Cementum is calcified connective tissue.

Dentin, a bonelike material, is under the enamel and makes up most of the tooth.

The pulp cavity includes blood vessels, lymphatics and nerves.



Hypsodont or high-crowned teeth

These are continue to erupt throughout life.

Examples of this type of teeth include all of the permanent teeth of [horses](#) and cheek teeth of [ruminants](#).

Hypsodont teeth are usually described as having a body, much of which is below the gum line, and root, which is embedded in the alveolus of the jaw bone.

Enamel covers the entire body of the tooth, but not the root.

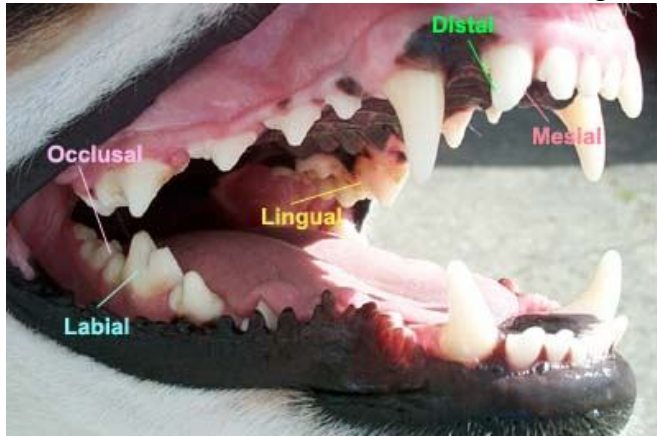In both high-crowned and low-crowned teeth, the tooth is attached to a "socket" in the jaw bone called an *alveolus*.

The attachment is through a fibrous capsule called the *gomphosis*.

Remembering the term gomphosis is required only of dental students.

An additional type of nomenclature is used to describe the different surfaces of teeth, as depicted in the image below.

The occlusal surface is the chewing surface.



Detailed information on [Dogs](#) dental anatomy.